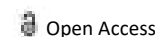




COMMENTARY



Liver Transplantation of Complications and Contraindications

Jan Marsa*

Department of Pathology, University of Cambridge, Cambridge, United Kingdom

ARTICLE HISTORY

Received: 01-Sep-2022, Manuscript No. JCMEDU-22-74145;
Editor assigned: 05-Sep-2022, PreQC No. JCMEDU-22-74145 (PQ);
Reviewed: 19-Sep-2022, QC No. JCMEDU-22-74145;
Revised: 26-Sep-2022, Manuscript No. JCMEDU-22-74145 (R);
Published: 03-Oct-2022

Description

A liver transplant is the replacement of a diseased liver with another person's healthy liver (allograft). Liver transplantation is a treatment option for end-stage liver disease and acute liver failure, although the availability of donor organs is a major limitation. The most common method is orthotopic transplantation, in which the native liver is removed and replaced with a donor organ in the same anatomical position as the original liver. The surgical procedure is complex, requiring careful collection of the donor organ and careful implantation of the recipient. Liver transplantation is strictly regulated and is performed only in designated medical transplant centers by highly trained transplant physicians and a supportive medical team. He was followed by Christoph Brotsch of the University of Chicago Medical Center in November 1989, when two-year-old Alice Smith received part of her mother's liver [1]. Eventually, surgeons realized that LDLT from an adult was also possible, and the practice is now common at several reputable medical institutes. It is considered technically more difficult than even a standard cadaveric donor liver transplant, and it also raises the ethical issues underlying the indication of a major surgical operation (hemihepatectomy or similar procedure) in a healthy person. In various case series, the donor's risk of complications is about 10%, and a second operation is very rarely required. Biliary fistula, gastric stasis and infections are common problems; they are more common after removal of the right lobe of the liver. Death after LDLT has been reported as 0% (Japan), 0.3% (USA), and <1% (Europe), with the risk likely to decrease further as surgeons gain more experience with the procedure [2]. Since the law was changed to allow altruistic undirected living organ donation in the UK in 2006, the first altruistic living liver donation took place in the UK in December 2012 [3].

Complications

The operation on a living donor is performed in a large center. Very few people need a blood transfusion during or after surgery. All potential donors should be aware that the chance of death is between 0.5 and 1.0 percent. Other risks of liver donation include bleeding, infection, painful incision, potential for blood clots, and prolonged recovery [4]. The vast majority of donors make a full recovery within 2-3 months [5]. Vascular complications include thrombosis, stenosis, pseudoaneurysm, and rupture of the hepatic artery [6]. Venous complications are less common than arterial complications and include thrombosis or stenosis of the portal vein, hepatic vein, or vena cava. Biliary complications include biliary stenosis, bile leak, and ischemic cholangiopathy. The risk of ischemic cholangiopathy increases with longer duration of cold ischemia, which is the time when the organ is deprived of blood flow (after death/removal before graft placement) [7].

Contraindications

Although liver transplantation is the most effective treatment for many forms of end-stage liver disease, the enormous limitation in allograft (donor) availability and widely variable outcomes after surgery make case selection critical. The assessment of a person's suitability for transplantation is carried out by an interdisciplinary team that includes surgeons, doctors, psychologists and other medical professionals.

The first step in the evaluation is to determine whether the patient has irreversible liver disease that can be cured by receiving a new liver [8]. Therefore, people with disease that is primarily extrahepatic or has spread beyond the liver are generally considered poor candidates. Some examples include:

- someone with advanced liver cancer with known/probable spread outside the liver
- active use of alcohol/psychic substances
- severe heart/lung disease
- existing high level of cholesterol in the patient
- a severe form of Wilson's disease
- dyslipidemia

References

- [1] Suh E, Daugherty CK, Wroblewski K, Lee H, Kigin ML, Rasinski KA, et al. General internists' preferences and knowledge about the care of adult survivors of childhood cancer. *Ann Intern Med* 2014; 160(1):11-7.
- [2] Umeshita K. Operative morbidity of living liver donors in Japan. *Lancet* 2003; 362(9385):687-90.
- [3] Ghobrial RM, Freise CE, Trotter JF, Tong L, Ojo AO, Fair JH, et al. Donor morbidity after living donation for liver transplantation. *Gastroenterology* 2008; 135(2):468-76.
- [4] Annarani IA, Lucas A, Ann CS, Gunaseeli SC. Liver Transplantation-A Case Report. *AJNER* 2021; 11(4):466-72.
- [5] Yao K, Bae L, Yew WP. Post-operative wound management. *Aust Fam Physician* 2013; 42(12):867-70.
- [6] Piardi T, Lhuair M, Bruno O, Memeo R, Pessaux P, Kianmanesh R, et al. Vascular complications following liver transplantation: A literature review of advances in 2015. *World J Hepatol* 2016; 8(1):36.
- [7] Memeo R, Piardi T, Sangiuolo F, Sommacale D, Pessaux P. Management of biliary complications after liver transplantation. *World J Hepatol* 2015; 7(29):2890.
- [8] Varma V, Mehta N, Kumaran V, Nundy S. Indications and contraindications for liver transplantation. *Int J Hepatol* 2011.